



## Congenital hairy polyp – A case report

## Kongenitalni dlakavi polip

Olgica Milankov\*<sup>†</sup>, Rajko Jović\*<sup>‡</sup>, Radojica Savić\*<sup>†</sup>, Milena Bjelica\*<sup>†</sup>

University of Novi Sad, \*Faculty of Medicine, Novi Sad, Serbia; Institute for Child and Youth Health Care of Vojvodina, <sup>†</sup>Department of Pediatrics, Novi Sad, Serbia; Clinical Center of Vojvodina, <sup>‡</sup>Clinic for Ear, Nose and Throat Diseases, Novi Sad, Serbia

### Abstract

**Introduction.** Hairy polyp is a rare malformation which consists of mesodermal and ectodermal elements. It is the most common congenital nasopharyngeal tumour. The clinical symptoms depend on the size and localization of the mass. Early surgical excision results in permanent cure. **Case report.** The child was born from regularly controlled pregnancy. Prenatally, in the 24th week of gestation, *epulis gigantocellularis* was suspected, magnetic resonance imaging confirmed existence of protruding mass. Immediately after the birth, a tissue formation connected with the hard palate was observed protruding out of the mouth, as well as split of soft palate and tongue. In the first day of life the child was intubated and a mechanical ventilatory support started. In the fourth day of life, tracheostomy was performed. In the 40th day of life, the tumor mass was entirely excised with the reconstruction of the existing deformity of the mouth. The histopathological analysis confirmed the diagnosis of hairy polyp. In the fifth month of life, a percutaneous endoscopic gastrostomy was placed. At the beginning of the second age, the split of tongue and soft palate was sewn. With the establishment of normal swallowing, decannulation and closing of tracheostomy were performed and then gastrostomy was closed. **Conclusion.** Although the hairy polyp is a rare tumor, it must be included in the differential diagnosis of pharyngeal mass in the neonatal period. If there are no associated anomalies and if complete surgical resection of the tumor is performed, further course of the treatment will be favourable.

### Key words:

cleft palate; diagnosis; histological techniques; infant, newborn; nasopharyngeal neoplasms; polyps; otorhinolaryngological surgical procedures.

### Apstrakt

**Uvod.** Dlakavi polip je retka malformacija koja se sastoji od mezodermalnih i ektodermalnih elemenata. To je najčešći kongenitalni tumor nazofarinksa. Klinički simptomi zavise od veličine i lokalizacije polipa. Rana hirurška ekscizija rezultuje potpunim izlečenjem. **Prikaz bolesnika.** Dete je rođeno iz redovno kontrolisane trudnoće. Prenatalno, u 24. gestacijskoj nedelji, postavljena je sumnja na postojanje *epulis gigantocellularis*-a. Urađena je magnetna rezonanca i evidentirana masa koja je protudirala iz usne duplje. Odmah po rođenju je uočena tkivna formacija vezana za tvrdo nepce, koja prominira van usta, kao i rasep mekog nepca i jezika. U prvom danu života dete je intubirano i započeta je mehanička respiratorna potpora. U 4. danu života izvršena je traheostomija, dok je u 40. danu života tumorska masa u celini ekscidirana, uz rekonstrukciju postojećih deformiteta u usnoj duplji. Histopatološka analiza je utvrdila postojanje dlakavog polipa. U petom mesecu života deteta izvedena je perkutana endoskopska gastrostoma. Na početku druge godine života rasep nepca i jezika je hirurški korigovan. Po uspostavljanju adekvatnog gutanja sprovedena je dekanilacija i zatvorena traheostoma i u daljem toku gastrostoma. **Zaključak.** Iako je dlakavi polip redak tumor, mora biti uključen u diferencijalnu dijagnozu faringealnih masa u neonatalnom periodu. Ukoliko nema pridruženih anomalija i ukoliko je izvršena kompletna hirurška resekcija tumora, dalji tok i ishod lečenja je povoljan.

### Ključne reči:

nepce, rasep; dijagnoza; histološke tehnike; novorođenče; nazofarinks, neoplazme; polipi; hirurgija, otorinolaringološka, procedure.

### Introduction

Hairy polyp is a rare malformation which consists of mesodermal and ectodermal elements, such as adipose, glandular and muscular tissues, covered by the epithelial squa-

mous stratified tissue<sup>1,2</sup>. A polyp is composed of the histologically mature tissue that is located in an area where it is not typically found. Although its classification and origin are the subject of constant debate, the authors agree that it is a benign lesion without the possibility of malignant alteration,

with a limited potential for growth<sup>2,3</sup>. Hairy polyp has been reported in the nasopharynx, soft and hard palate, tongue, oropharynx, tonsil, palatopharyngeus and palatoglossus muscles, external auditory canal, middle ear, mastoid, hypopharynx, oesophagus and trachea<sup>4</sup>. It is the most common congenital nasopharyngeal tumour<sup>5</sup>.

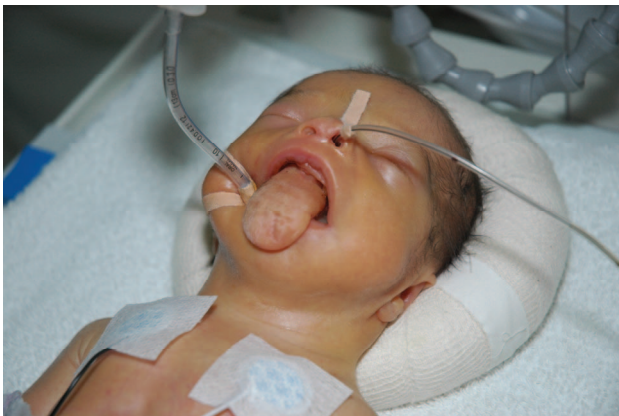Hairy polyp is more often seen in females, mostly in newborns, rarely in adults<sup>2,6</sup>.

The clinical symptoms depend on the size and localization of the mass. It is typically presented by polyhydramnios in the prenatal period and by shortness of breath, stridor and problem with swallowing soon after the birth.

Early surgical excision results in permanent cure<sup>3,5</sup>.

### Case report

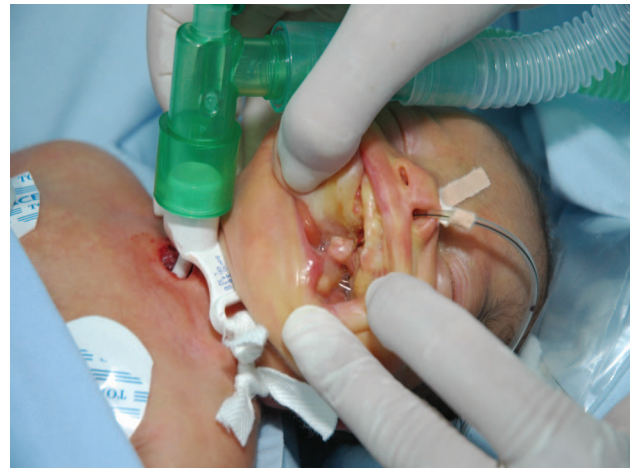The female child was born as a second twin from regularly controlled pregnancy. Prenatally, in the 24th week of gestation, *epulis gigantocellularis* was suspected, the magnetic resonance imaging (MRI) was done and a protruding mass was detected, arising probably from the gingiva of alveolar part of the maxilla. During pregnancy, the polyhydramnios was detected. The child was born in the 33rd gestational week by a caesarean section due to premature contractions of the mother. Its birth weight was 1,720 g, the Apgar score 3/6. Immediately after the birth, a tissue formation connected with the hard palate was observed, protruding out of the mouth, sized 9 × 3 cm, as well as the split of soft palate and tongue. In the floor of the oral cavity cartilaginous-skeletal-fibrous tumefaction was detected. Other anomalies were not noticed.



**Fig. 1 – Intubated newborn with the hairy polyp.**

In the first day of life, the child was intubated and the mechanical ventilatory support and nutrition through a nasogastric tube started (Figure 1). Computed tomography of the head and neck was done: the soft tissue formation was detected; it originated from the connection of the middle and the last third of the roof of the oral cavity, protruding out of the mouth till the lower edge of mandible. A skeletal malformation sized 13.5 mm was detected on the left side of the bottom of the oral cavity, originating from the dental alveoli of the second and third tooth protruding medially and forward basis of the tongue. Karyotype was normal. In the

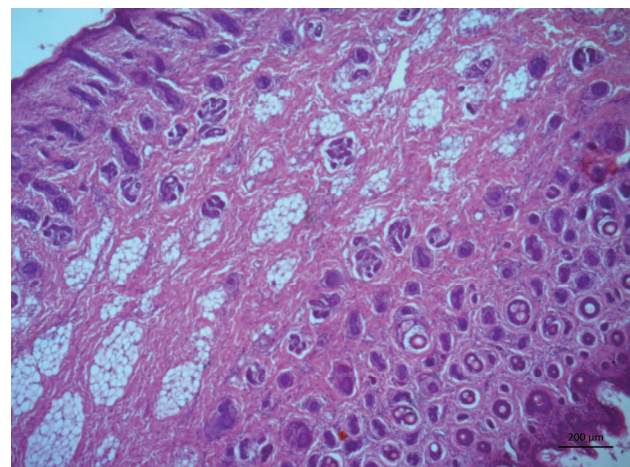
fourth day of life, tracheostomy was performed, and until the definitive operative treatment, the mechanical ventilation support was continued (Figure 2).



**Fig. 2 – Newborn with the hairy polyp after a tracheostomy.**

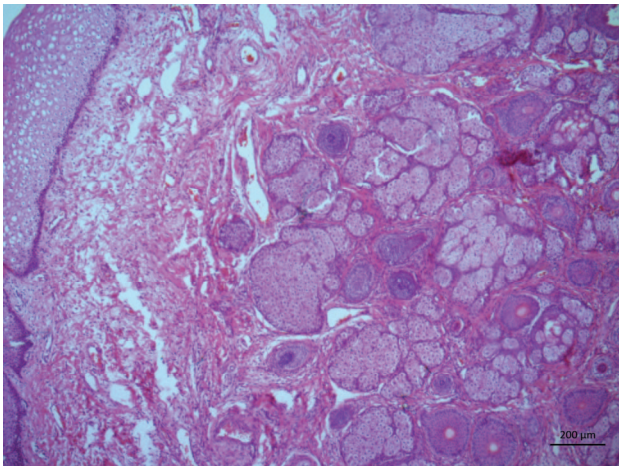
The child developed the clinical and radiological signs of respiratory distress syndrome. In the third week of life, seizures occurred, so an anticonvulsant therapy (phenobarbital) was introduced. The antimicrobial therapy during hospitalisation was conducted according to the antibiogram (ceftazidime, vancomycin). In addition to inhaled corticosteroids, in order to prevent a chronic lung disease, parenteral corticosteroid (dexamethasone) was introduced. In the 40th day of life, a surgery was performed, the tumor mass was entirely excised with the reconstruction of the existing deformity of the mouth (unilateral mandibular osteotomy). The material was sent for a histopathological analysis. The result was a hairy polyp with stratified squamous epithelium on the surface with hair follicles, sebaceous and sweat glands, as well as lobular mature fatty tissue in the deeper layer (Figures 3 and 4).

Upcoming 7 days, the child was on the mechanical ventilatory support, and then she was separated from the ventilator and furthermore was on the oxygen therapy.



**Fig. 3 – Photomicrograph of the hairy polyp shows a lining of stratified squamous epithelium with hair follicles, sebaceous and sweat glands and fatty tissue (HE, ×50).**

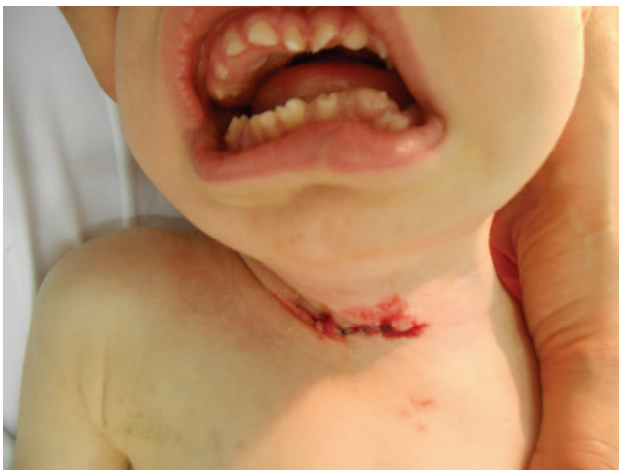



**Fig. 4 – Photomicrograph of hair follicles and sebaceous glands of hairy polyp (HE, ×50).**

The further course of treatment was complicated by the appearance of pulmonary infection and sepsis, so the adequate antimicrobial therapy (ceftazidime, ciprofloxacin and amikacin) was implemented. Because of this, the child was hospitalized during the first six months of life. In the fifth month of life, a percutaneous endoscopic gastrostomy was placed, so further feeding was conducted this way. Considering the fact that during the whole hospitalization period the child was on oxygen therapy, in the sixth month of life, she was released from hospital with the oxygen concentrator. Later on, there was no sign of residual tumor. Because of the postoperative cicatrization and presence of cleft palate and tongue, upon the advice of the plastic surgeon, palatoplasty was planned after the age of one year.

At the beginning of the second year, the split of tongue and soft palate was sewn. With the establishment of normal swallowing, decannulation and closing of tracheostomy were performed (Figure 5), and then gastrostomy was closed.



**Fig. 5 – The child, 2 years after corrective operation and closing of tracheostomy.**

### Discussion

Hairy polyp is a rare benign tumor, with an incidence 1:40,000 births<sup>2</sup>. In the published cases there is a distinct

female preponderance, 6:1, however, there is no evidence of any genetic inheritance<sup>3</sup>. The presented case underlines the predominance of females. Hairy polyp is usually localized in the nasopharynx, often arising from the soft palate and lateral pharyngeal wall<sup>4,5</sup>. In our patient, the tumor was arising from the hard palate. Macroscopically, the tumor usually presents as a sausage or pear-shaped, pedunculated mass, with the size which can range between 0.5 and 6 cm<sup>1,4</sup>. In our patient size of the tumor was bigger than usual – 9 × 3 cm.

There is not a consistent classification of hairy polyps in the literature<sup>1</sup>. Histological examination is crucial in differentiating a hairy polyp from other lesions, such as teratomas, hamartomas, dermoids and choristomas. A hairy polyp is made of tissue of mesodermal and ectodermal origin. The mesodermal components can be fibroadipose tissue, muscle and cartilage. The ectodermal components can be mature stratified squamous epithelium with skin appendages<sup>4</sup>. Unlike hairy polyps, teratomas have the tissue from all three germinal cell layers, they occur equally in males and females and malignant transformation is possible. Hamartomas consist of excessive histologically normal tissue for a particular localisation. Since the pharynx does not contain stratified squamous epithelium, hairy polyps cannot be classified to this group. Dermoids are cystic lesions that contain the desquamated epithelial products. Polyps do not include the ectodermal inclusion cysts within its mesodermal core<sup>1,4,7</sup>. According to Arnold<sup>8</sup>, a classification from 1870, hairy polyp is classified as dermoid. A choristoma is a mass consisting of a histologically normal tissue in an anatomically abnormal location. According to some authors, hairy polyps are included into this group<sup>1,4,7-10</sup>. The terms as bigerminal choristomas, choristomatous hairy polyps, hairy teratoid polyps, nasopharyngeal dermoids are used in the literature<sup>7,10,11</sup>.

In our case, the ectodermal elements such as stratified squamous epithelium with skin appendages, as well as the mesodermal structures in the form of adipose tissue were described histologically.

The origin of hairy polyps remains unclear and it is questionable whether they belong to the developmental malformations, or primitive teratomas<sup>7</sup>. There are several proposed theories for its embryogenesis: (1) escape of pluripotent tissue from normal control mechanisms before the 4th week of gestation, disturbed development during the fusion of the epiblast of the stomodeum with the anterior foregut and failure in closure of the 2nd pharyngeal cleft, (2) failure of the nasopharyngeal membrane to regress during the 7th week of gestation, (3) parasitic fetus, derived from the misdirected pluripotent cells that have bypassed the influences appropriate for the local environment, (4) the first pharyngeal apparatus in germ cell rests, (5) inclusion dermoid cyst between two germ layers of the 1st and 2nd branchial arches, (6) inclusion errors in the fusion of the lateral palatal process during the 10th week of embryogenesis, (7) accessory auricles arising from the 1st pharyngeal arch, (8) choristomatous developmental anomalies originating from the 1st branchial cleft area, (9) escape of pluripotential tissue as a disorganized mass, and (10), developmental malformations

related to the development of 1st and 2nd pharyngeal arches<sup>7,9,10</sup>.

As additional diagnostic procedure, a cytogenetic studies could be done to determine the germ cell origin of a neoplasm of the head and neck. Malignant tumors frequently carry a characteristic chromosomal gain of 12 p, while benign tumors (mature teratomas) show no chromosomal abnormalities<sup>12</sup>.

In 10% of cases, the hairy polyps are associated with other first, or second branchial arch malformations, and in another 10% of cases, they are associated with a cleft palate, since the existence of the polyp may interfere with the closure of the palatal shelves<sup>1,13</sup>. The association of hairy polyps with various congenital malformations has been described, such as cleft lip and palate, facial hemihypertrophy, agenesis of the uvula, external auricle, left carotid artery atresia, ankyloglossia and osteopetrosis. The cleft palate and tongue was detected in our patient.

Polyhydramnios is usually observed during pregnancy because the existence of a polyp disables adequate swallowing mechanism of the foetus<sup>3</sup>. This was also noted in our case. A polyp may partially, or completely obstruct the way to the trachea or oesophagus giving the symptoms of the respiratory or gastrointestinal tract<sup>14-16</sup>. Depending on the location and size, polyps can give symptoms immediately after birth, but they may also accidentally be discovered in late childhood and exceptionally in adults<sup>1,7</sup>. The most common symptoms at birth are asphyxia, respiratory distress, stridor, cyanosis, feeding difficulties, hypersalivation and recurrent cough. They can also be presented by dysfunction of the Eustachian tube, obstructive sleep apnea or snoring, haemoptysis and persistent nasal secretion<sup>3,7,16</sup>. Most of these symptoms were also recorded in our patient. It must be noted that, apart from the presence of pharyngeal mass, the premature birth of our patient certainly contributed to the expression of these symptoms.

A hairy polyp might be overlooked during the endotracheal intubation, because it is usually mobile, soft and pedunculated<sup>3</sup>. Small hairy polyps may be lethal because of delayed diagnosis. To locate small hairy polyps, the physicians should not hesitate to perform further examination because there is the possibility of oversight with only physical examination<sup>17</sup>. Radiological investigations are important to determine the size and location of the tumor, to exclude intracranial expansion, to differentiate it from other masses, to

determine the presence of any other associated anomalies and to plan a surgical treatment<sup>4</sup>. For these reasons, in our patient, the computed tomography was performed immediately after birth and it determined the size and location of the tumor mass.

The differential diagnosis of a neonatal nasopharyngeal mass includes teratoma, craniopharyngioma, meningoencephalocele, nasal glioma, neuroblastoma, haemangioma, rhabdomyosarcomas, thymic-thyroglossal or a lingual cyst<sup>1,3,4,11</sup>.

A prenatal diagnosis of nasopharyngeal masses is uncommon. If a prenatal ultrasound does show a head and neck mass, the likelihood of perinatal airway obstruction is high. This finding should alert the physician in charge to the potential risk and appropriate prenatal planning should occur<sup>11</sup>. Perinatal management of oropharyngeal masses involves either intrapartum intubation [*ex utero* intrapartum treatment (EXIT procedure)], or resection of the tumor at the time of the cesarean section and prior to cutting the umbilical cord [operation on placental support (OOPS)]<sup>18</sup>. The EXIT procedure can be done in cases where difficulty is anticipated in neonatal airway establishment at delivery, and is done at the time of caesarean section. The partially delivered fetus is maintained on placental circulation while airway is established<sup>19,20</sup>. *In utero* resection of an oral mass via operative fetoscopy is also one of the therapeutic possibilities<sup>18</sup>.

The treatment of choice for this type of tumor is a surgical removal. No recurrence has been reported after complete excision<sup>4</sup>. By monitoring our patient, we confirmed the previous statement. In some published cases the autoamputation of the tumor is described, which resulted in a complete recovery<sup>3,21</sup>.

## Conclusion

Although the hairy polyp is a rare tumor, it must be included in the differential diagnosis of pharyngeal mass in the neonatal period. Its presence must be considered in case of breathing and feeding difficulties in infants. The radiological examination can help us in a quick and clear orientation and preparation for the surgery, which should be performed as soon as possible. The final diagnosis is made by obtaining the histological findings. If there are no associated anomalies, and if complete surgical resection of the tumor is performed, further course of the treatment will be favourable.

## R E F E R E N C E S

1. Budenz CL, Lesperance MM, Gebarski S. Hairy polyp of the pharynx obscured on physical examination by endotracheal tube, but diagnosed on brain imaging. *Pediatr Radiol* 2005; 35(11): 1107-9.
2. Puricelli E, Barra MB, Hochbegger B, Ponzoni D, de Azambuja HV, Morganti MA, et al. Hairy polyp on the dorsum of the tongue. *Head Face Med* 2012; 8: 19.
3. Cheriathu JJ, Mohamed K, D'Souza IE, Shamseldeen M. Autoamputation of congenital hairy polyp in neonate with stridor and respiratory failure. *WebmedCentral Paediatrics* 2012; 3(5): WMC003379.
4. Christianson B, Ulualp SO, Koral K, Rekebeja D, Deskin R. Congenital hairy polyp of the palatopharyngeus muscle. *Case Rep Otolaryngol* 2013; 2013: 374681.
5. Baljošević I, Minić P, Đuričić S, Šubarević V. Congenital hairy polyp of the nasopharynx: A case report. *Med Pregl* 2007; 60(3-4): 191-3. (Serbian)
6. Singh D, Darabwal A, Banjara H, Sarkar S. Hairy polyp of the nasopharynx. *AJCR* 2011; 4(3): 149-51.
7. Dutta M, Roy S, Ghatak S. Naso-oropharyngeal choristoma (hairy polyps): An overview and current update on presenta-

- tion, management, origin and related controversies. *Eur Arch Otorhinolaryngol* 2015; 272(5): 1047–59.
8. *Arnold J*. Ein Fall von congenitalem zusammengesetztem Lipom der Zunge und des Pharynx mit Perforation in die Schädelhöhle. *Virchows Arch (Pathol Anat)* 1870; 50: 482–516.
  9. *Kelly A, Bough ID, Luft JD, Conard K, Reilly JS, Tuttle D*. Hairy polyp of the oropharynx: case report and literature review. *J Pediatr Surg* 1996; 31(5): 704–6.
  10. *Simoni P, Wiatrak BJ, Kelly DR*. Choristomatous polyps of the aural and pharyngeal regions: first simultaneous case. *Int J Pediatr Otorhinolaryngol* 2003; 67(2): 195–9.
  11. *Coppit GL 3rd, Perkins JA, Manning SC*. Nasopharyngeal teratomas and dermoids: A review of the literature and case series. *Int J Pediatr Otorhinolaryngol* 2000; 52(3): 219–27.
  12. *Vranic S, Caughron SK, Djuricic S, Bilalovic N, Zaman S, Suljevic I*, et al. Hamartomas, teratomas and teratocarcinosarcomas of the head and neck: Report of 3 new cases with clinicopathologic correlation, cytogenetic analysis, and review of the literature. *BMC Ear Nose Throat Disord* 2008; 24(8): 8.
  13. *Aughton DJ, Sloan CT, Milad MP, Huang TE, Michael C, Harper C*. Nasopharyngeal teratoma ('hairy polyp'), Dandy-Walker malformation, diaphragmatic hernia, and other anomalies in a female infant. *J Med Genet* 1990; 27(12): 788–90.
  14. *Cone BM, Taweesit M, Shenoda S, Sobol S, Schemankewitz E, Shehata BM*. Pharyngeal hairy polyps: five new cases and review of the literature. *Fetal Pediatr Pathol* 2012; 31(3): 184–9.
  15. *Richter A, Mysore K, Schady D, Chandu B*. Congenital hairy polyp of the oropharynx presenting as an esophageal mass in a neonate, a case report and literature review. *Int J Pediatr Otorhinolaryngol* 2016; 80: 26–9.
  16. *İsmi O, Gövür K, Arpacı RB, Vayisoglu Y, Özcan C*. Hairy polyp of the supratonsillar fossa causing intermittent airway obstruction. *Int Arch Otorhinolaryngol* 2015; 19(1): 90–2.
  17. *Koike Y, Uchida K, Inoue M, Ohtsu K, Tanaka T, Otake K*, et al. Hairy polyp can be lethal even when small in size. *Pediatr Int* 2013; 55(3): 373–6.
  18. *Kontopoulos EV, Gualtieri M, Quintero RA, Siristatidis C, Vrachnis N, Chrelias C*. Successful in utero treatment of an oral teratoma via operative fetoscopy: case report and review of the literature. *Am J Obstet Gynecol* 2012; 207(1): e12–5.
  19. *Laje P, Howell LJ, Johnson MP, Hedrick HL, Flake AW, Adzick SN*. Perinatal management of congenital oropharyngeal tumors: the ex utero intrapartum treatment (EXIT) approach. *J Pediatr Surg* 2013; 48(10): 2005–10.
  20. *Abraham RJ, Sau A, Maxwell D*. A review of the EXIT (Ex utero Intrapartum Treatment) procedure. *J Obstet Gynaecol* 2010; 30(1): 1–5.
  21. *De Caluwe D, Kealey SM, Hayes R, Puri P*. Autoamputation of a congenital oropharyngeal hairy polyp. *Pediatr Surg Int* 2002; 18(5–6): 548–9.

Received on October 16, 2017.

Accepted on November 09, 2017.

Online First November, 2017.